

Intraneural cyst of peripheral nerve: scientific literature review and clinical case analyze

L. V. Khimion¹, L. S. Tymoshchuk¹, N. V. Kicha¹, T. O. Sytiuk¹, S. V. Danyliuk¹, T. M. Povetkina¹, O. S. Chernyak², I. P. Urupa², O. V. Dzyhar³

¹Shupyk National Healthcare University of Ukraine, Kyiv

²Municipal non-commercial enterprise of Kyiv regional council «Kyiv regional clinical hospital», Kyiv

³SI «The Institute of Traumatology and Orthopedics», NAMS of Ukraine, Kyiv

An intraneural ganglion cyst is a non-neoplastic formation that develops in the epineurium and is difficult to diagnose. At the same time, the formation causes pronounced sensorimotor disturbances along the affected nerve, which can become irreversible in case of long-term existence, delays in diagnosis and treatment, thus significantly impairing the patient's health and limiting the patient's mobility.

The objective: to analyze the modern scientific sources on the morphology, diagnosis and effective methods of treatment of intraneural ganglion cysts (INGC) and to apply these data to describe a case from the clinical practice of Ukrainian specialists.

Materials and methods. Information was searched in scientific sources PubMed, Medscape, ResearchGate, Scientific periodical of Ukraine, Vernadsky National Library of Ukraine regarding the diagnosis, morphology, pathogenesis and modern approaches to the treatment of ganglion intraneural cysts. The obtained data are illustrated by clinical case, which is a first published case description of INGC in Ukraine.

Results. According to the analyzed scientific medical literature, INGC mostly was not recognized as a separate pathology until the 90s of the 20th century, because there were no imaging diagnostic methods with sufficient resolution for precise diagnosis, so INGC was described as an abscess, cystic schwannoma, etc. Also there were "curious" cystic findings in epineurium made from 1810 till 1998 [1]. No description of this pathological condition was found in Ukrainian publications. At present recommended diagnostic method is MRI; early surgical intervention is recommended as the only effective treatment to prevent the development of irreversible nerve changes.

The article provides review and analyze of the scientific data and illustrated by detailed description of the clinical case of INGC - symptoms, diagnostic examinations, surgical treatment and postoperative followup results.

Conclusions. The awareness of doctors of various specialties with the clinical and imaging signs of INGC, treatment methods will allow more effective early detection and timely treatment of patients, since this rare condition can cause irreversible sensory-motor nerve damage. At the same time, an early surgical intervention practically guarantees a full recovery.

Keywords: intraneural ganglion cyst (INGC), magnetic resonance imaging, ultrasound examination, peripheral nerves, nerve surgery.

Інтраневральна кіста периферичного нерва: огляд досліджень та опис клінічного випадку

Л. В. Хіміон, Л. С. Тимошук, Н. В. Кіча, Т. О. Ситюк, С. В. Данилюк, Т. М. Поветкіна, О. С. Черняк, І. П. Урупа, О. В. Дзигар

Інтраневральна гангліозна кіста є непухлинним утворенням, що розвивається в епіневрумі в важко діагностується. Водночас дане утворення спричинює виражені сенсорно-моторні порушення вздовж стовбура ураженого нерва, які можуть бути необоротними при тривалому існуванні, затримками в діагностиці та лікуванні, істотно порушуючи стан здоров'я та обмежуючи рухливість пацієнта.

Мета дослідження: аналіз сучасних наукових джерел щодо морфології, діагностики та ефективних методів лікування інтраневральних гангліозних кіст (ІНГК) та використання цих даних для опису випадку з клінічної практики українських спеціалістів.

Матеріали та методи. Проведено пошук інформації в наукових джерелах PubMed, Medscape, Researchgate, Наукова періодика України, Національна бібліотека України імені В. І. Вернадського щодо виявлення, морфології, патогенезу розвитку та сучасних підходів до лікування гангліозних інтраневральних кіст. Одержані дані проілюстровано клінічним випадком, що буде вперше опубліковано в науковій публікації в Україні.

Результати. За даними проаналізованої наукової медичної літератури, ІНГК як окрема патологія була маловідомою до 90-х років ХХ століття, позаяк не існувало сучасних візуалізаційних методів діагностики з достатньою роздільною здатністю для проведення точної діагностики. Саме тому ІНГК описували як абсцес, кістозну шванному тощо. Водночас з 1810 по 1998 рр. були описані «куриозні» знахідки у вигляді кіст в епіневрумі під час проведення патанатомічних досліджень. У вітчизняних джерелах не знайдено жодного опису даного патологічного стану. Рекомендованим методом діагностики є застосування МРТ, для лікування необхідним є проведення раннього хірургічного втручання з метою запобігання розвитку необоротним змінам нерва.

Представлений огляд і аналіз сучасних наукових джерел проілюстровано клінічним випадком ІНГК, простеженням від симптомів, діагностичних обстежень до деталей хірургічного лікування та результатів післяопераційного контролю стану пацієнта.

Висновки. Обізнаність лікарів різних спеціальностей із клінічними, візуалізаційними ознаками ІНГК та методами лікування дозволить ефективніше виявляти та вчасно лікувати пацієнтів, оскільки цей рідкісний стан може викликати необоротні сенсорно-моторні ураження нерва. Водночас вчасно проведене хірургічне втручання практично гарантує повне одужання.

Ключові слова: інтраневральна гангліозна кіста, магнітно-резонансна томографія, ультразвукова діагностика, периферичні нерви, хірургічне лікування.

An intraneural ganglion cyst (INGC) is a non-neoplastic mucinous formation in the epineurium of a peripheral nerve, which typically leads to the symptoms of peripheral neuropathy due to displacement and compression of the nerve bundles. These cysts are filled with mucinous contents, which are separated from other tissues by a fibrous layer [1].

The etiopathogenesis of these formations remains undetermined even today, and in the scientific literature there are even different names for this pathology - for example - intraneural pseudocyst.

A ganglion is a cystic structure that has an inner lining formed by flat spindle cells and contains mucin [2, 3]. Most often, such formations occur in the perineurium of the peroneal nerves; however, they can also form in the peripheral nerves of the upper limbs (ulnar, radial nerve). Theories of the INGC pathogenesis are still remain controversial. At present the most proven and accepted is the theory of cyst formation as a result of development of communication channel between the nearest synovial joint and the epineurium of the corresponding peripheral nerve («articular theory») [4].

The capsular defect of the synovial joint or the formation of a pedunculus of the membrane, for example, as a result of an injury, leads to the move of synovial fluid into the articular branch of the nerve. Further, the pressure of the synovial fluid contributes to the flow of a certain amount of synovial content directly to the epineurium, which can cause symptoms of the nerve bundles compression; at this time the fluid can be organized into a cyst-like formation [2, 3]. Thus, taking into account this etiopathogenetic mechanism, it is necessary to find and disconnect the channel of communication between cyst and synovium of the joint during surgical intervention for cyst relapses prevention.

The clinical appearance of INGC is associated with the displacement and compression of the nerve bundles, which leads to pain, paresthesia, and muscle problems in the innervation zones of the involved nerve. During the clinical evaluation of the involved nerve, it is possible to detect surface thickening and varying degrees of sensor-motor disturbances along its distribution. The clinical picture of intermittent motor paralysis and sensory disturbances at an acute onset may mimic other pathological conditions, such as radiculopathy, pathology of the pelvis and shoulder, and may complicate and delay proper diagnosis.

The diagnosis of INGC can be confirmed by imaging techniques such as magnetic resonance imaging (MRI) and high-resolution ultrasound.

Nerve paralysis is usually reversible if the nerve is surgically decompressed at an early stage. To prevent recurrence, the connection of the cyst with the joint should be identified and destroyed during surgery. In the world literature, clinical cases of intraneural ganglion cyst of the radial, ulnar, sciatic, peroneal and calf nerves are described.

At the same time, it should be noted that despite the evidence and confirmation of the articular theory in the

pathogenesis of INGC of the sciatic and peroneal nerves, no connection of the cyst with the elbow joint was detected during surgical interventions for INGC of the ulnar nerve [4].

Taking into account rather rare character of this pathology, it is rational to describe and publish all clinical cases for their further systematization and analysis with the aim to achieve a progress in understanding of the pathogenetic mechanisms of the cyst formation and, accordingly, use of the most effective approaches to treatment.

MATERIALS AND METHODS

This article describes and analyzes a clinical case of an intraneural ganglion cyst of the sciatic and peroneal nerves, for the first time in Ukrainian scientific literature.

RESULTS AND DISCUSSION

No published case of intraneural ganglion cyst of the sciatic and peroneal nerves was found in the Ukrainian sources. Therefore, presenting this clinical case will help to enrich knowledge about various manifestations and course of intraneural ganglion cyst of sciatic and peroneal nerves, and early diagnosis will help to achieve success in surgical treatment and regression of neurological consequences.

Clinical case

Patient T., DOB 01.04.1975, male, had pain in the knee joint, periodical weakness and numbness in calf and foot of the right leg for more than a year. Before the appearance of these symptoms, he was healthy, did not have any medical history in the past. The pain had a burning character, occurred periodically, sometimes reaching an unbearable level, when patient could not walk more than 200 m.

Decrease in physical activity and rest of the limb brought relief, the pain went away on its own without taking any remedies. The patient underwent an outpatient ultrasound examination (US) of the extremities and received the result: deep vein thrombosis (DVT) and rupture of the Baker's cyst of the right leg. Appropriate treatment was prescribed, which brought some relief to the patient, probably due to prescribed restful regimen. Subsequently, the clinical signs progressed in a wave-like manner, and after some time the patient began to notice the increase in weakness of dorsiflexion and abduction of the right foot.

In the conditions of martial law, the patient was conscripted into the military, and was referred for the medical evaluation. Having a history of DVT, he had been sent for consultation to vascular surgeon, who in turn recommended an ultrasound of the veins of the lower extremities to clarify the diagnosis.

Prior to instrumental examinations, the patient underwent a comprehensive laboratory examination. Below are the results of the lab tests.

27.01.2023. D-dimer – 0.27 mg/l (N <0.5 mg/l).

22–28.03.2023. Biochemistry: ALT – 26.0 U/L (N <50 U/L), AST – 19.2 U/L (N <40 U/L), GGT – 19.2 U/L

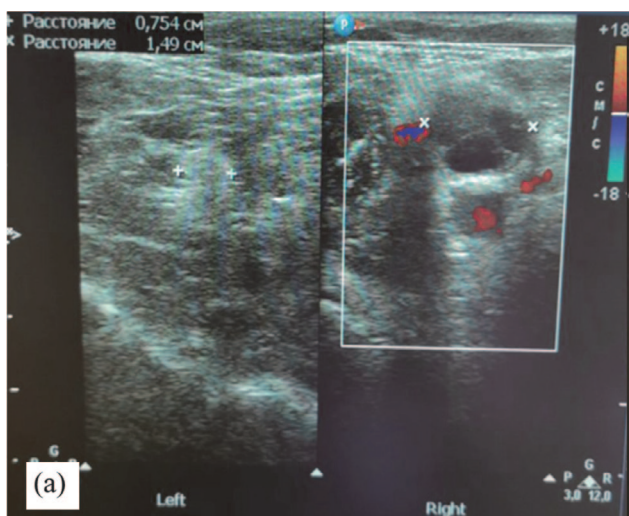


Fig. 1a. Ultrasound examination of the soft tissues of the thigh of the lower extremities, transverse image. Comparative images of the right and left sciatic nerves. Bulky formation of the soft tissues of the thigh of the right lower limb

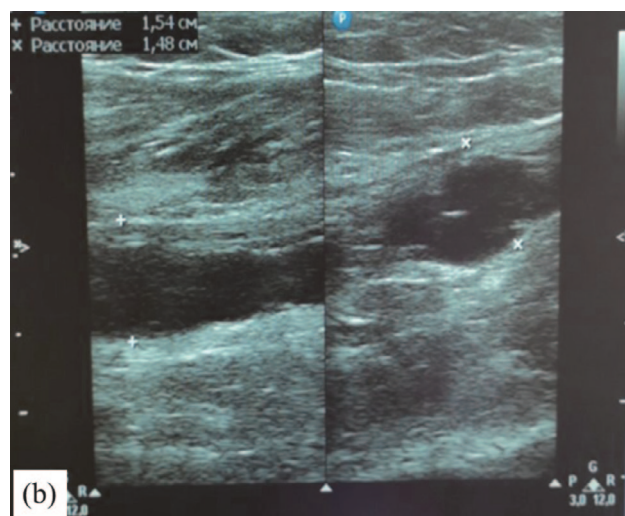


Fig. 1b. Ultrasound examination of the soft tissues of the thigh of the lower limbs, longitudinal image. Bulky formation of soft tissues of the thigh of the right lower limb

(N 8–61 U/L), total protein – 74.4 g/L (N 66–87 g/L), creatinine – 86.2 $\mu\text{mol/l}$ (N 62–106 $\mu\text{mol/l}$), urea – 5.7 mmol/l (N 2.76–8.07 mmol/l), glucose – 6.52 mmol/l (N 4.11–5.89 mmol/l), HbA1c 5.7% (N 5–6%), total bilirubin – 10.1 $\mu\text{mol/l}$ (N 1.7–21 $\mu\text{mol/l}$), rheumatoid factor – <9.9 IU/ml (N <14 IU/ml), uric acid – 331.4 $\mu\text{mol/l}$ (N 202.3–416.5 $\mu\text{mol/l}$), antibodies to thyroperoxidase 14.98 IU/ml (N <34 IU/ml), thyroxine free T4 – 1.22 ng/dL (N 0.93–1.70 ng/dL), thyroid-stimulating hormone – 4.04 $\mu\text{IU/ml}$ (N 0.27–4.2 $\mu\text{IU/ml}$).

Hematology and urinalysis – normal.

19.04.2023. Ultrasound of the veins of the lower limbs: Superficial and deep veins of the right lower limb are passable. Thrombosis was not detected. Blood reflux is not recorded. On the back surface of the limb, extending from the middle third of the thigh to the middle third of the calf, at a depth of up to 30 mm from the surface of the skin on the thigh and 15 mm on the calf, along the way of the sciatic nerve on the thigh and the vascular-nerve bundle in the popliteal fossa, and along the peroneal nerve on the cruris, - an avascular, anechoic tubular structure is visualized, 16–17 mm thick, with a clear uneven contour, with linear hyperechoic layers present, that create the appearance of «cells» (Fig. 1a, b).

Visual connection with the main vessels, the knee joint was not detected. Conclusion: ultrasound signs of impaired blood flow in the veins of the right lower limb were not detected. Bulky formation of the soft tissues of the thigh of the right leg (Disease of the sciatic nerve? Differential diagnosis: lymphoma, neuroma, neurofibroma, perineurinoma?).

The next stage of examination was MRI, as this method is the method of choice for the nerves surrounding soft tissues visualization

18.04.2023. MRI of the soft tissues of the right leg (Fig. 2, 3). A series of MR tomograms of the right lower extremity revealed uneven expansion of the anterior and posterior tibial, popliteal, and deep femoral veins

up to 13 mm, up to 300 mm long, with heterogeneous hyperintense on T2 and weakly hyperintense on T1 W1 with signs of diffusion restriction, which is more likely due to thrombosis. Moderate swelling of the interfascial fatty tissue is determined by the course of these vessels. Posterior tibialis muscle with signs of interstitial edema. Pathological changes in MR signal intensity from thigh muscles are not detected. The femur is intact. Lymph nodes are unchanged in size and structure. Conclusion: DVT of the right lower extremity without signs of recanalization.

20.04.2023. MRI of the right leg consultation (middle lower third of the thigh, upper third of the lower leg from 18.04.2023). An MR tomogram shows uneven expansion of the veins of the lower limb, namely the anterior and posterior tibial, popliteal, and deep veins of the thigh, up to 15 mm in diameter, with a total length of up to 300 mm. Slight swelling of the surrounding fatty tissue. Muscles of the thigh and lower leg without visible changes. The MR signal from the bone marrow of the femur, tibia and fibula is unchanged. Conclusion: at the time of examination, there were signs of varicose changes of the anterior and posterior tibial veins, the popliteal and deep veins of the thigh with signs of slight edema of the surrounding fatty tissue, which may correspond to the residual changes of the previous acute thrombosis. Additionally: a stress fracture of the medial meniscus, synovitis of the left knee joint is determined.

As we can see both MRI evaluations (made on 18.04.2023 and 20.04.2023 – as a second opinion by another radiologist) were focused on venous pathology, but at the same time had significant differences between them, as they described the state of DVT in the acute stage in the first case, and the residual phenomena of past thrombosis in the second. Taking into account the conflicting results of the two evaluations, a decision was made to get an additional independent consultation of MRI images at an alternative medical institution. To compare the conclusions, we present the third MRI description.

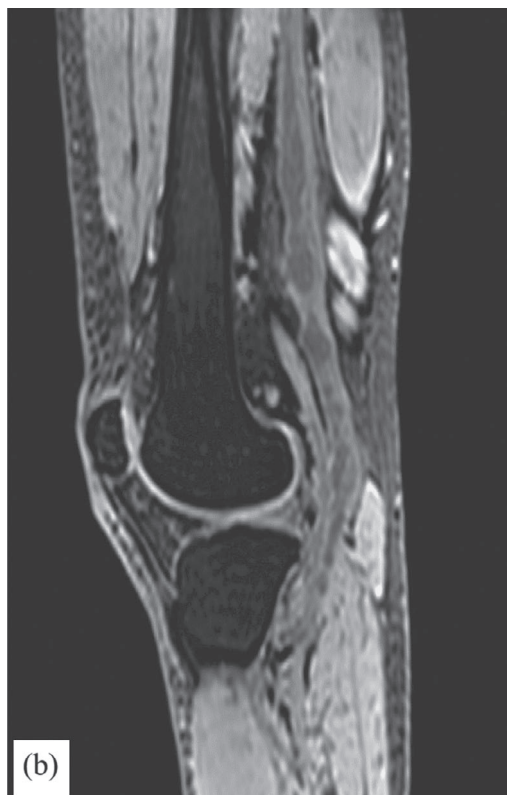
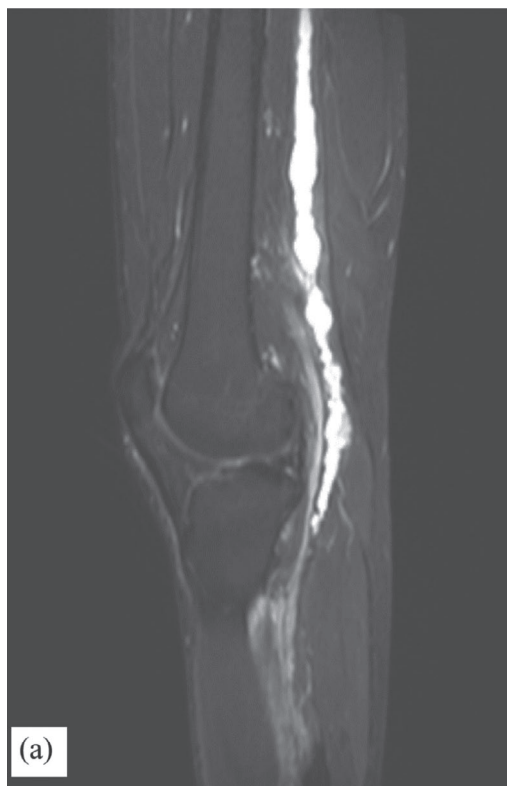


Fig. 2. Magnetic resonance imaging of the lower extremity (middle and lower thirds of the thigh, upper third of the calf), sagittal images in the STIR mode (a) and in the THRIVE (3D T1) mode (b). Cyst-like changes along the course of the sciatic and common peroneal nerves

20.04.2023. In the projection of the sciatic nerve of the right leg with extension to the level of the bifurcation and proximal parts of the common peroneal nerve, a tubular-shaped, uneven diameter ($\approx 9\text{--}16\text{ mm}$), cyst-like formation (high signal in T2-weighted image, reduced signal in T1-weighted images), with fairly clear contours is present. Surrounding adipose tissue with minimal MR signal enhancement on STIR images due to edema. On the presented DWI images, the formation shows no signs of diffusion restriction (measurable diffusion coefficient $\approx 2.1\text{--}2.7 \times 10^{-3}\text{ mm}^2/\text{s}$).

The superficial femoral artery and vein as well as popliteal artery and vein were found in a typical places with unchanged appearance (uniform width with clear and even contours, hypointense signal in T2, STIR images). At the same time, moderately pronounced diffuse edema of the popliteal muscle was visualized. In the area of the medial process of the tibia of the right knee joint, a diffuse uneven trabecular edema is visualized, a significant amount of effusion is noted in the joint and adjacent bags.

Conclusion: MR signs of a cyst-like formation in the projection of the sciatic and common peroneal nerves, which may be caused by an intraneural ganglion cyst.

Taking into account the complaints, the clinical course of the disease, its duration, the diagnostic search was directed to determine the nature of the cyst, which was detected by ultrasound and MRI. In order to rule out the nerve damage, in addition to the clinical neurologic examination and imaging methods, it was recommended to perform electrophysiological studies, including electromyography and nerve conduction studies.

21.04.2023 the patient underwent electroneuro-myography (ENMG). Conclusion of ENMG: during the examination of the lower extremities, a decrease in the muscle response to stimulation of the right peroneal

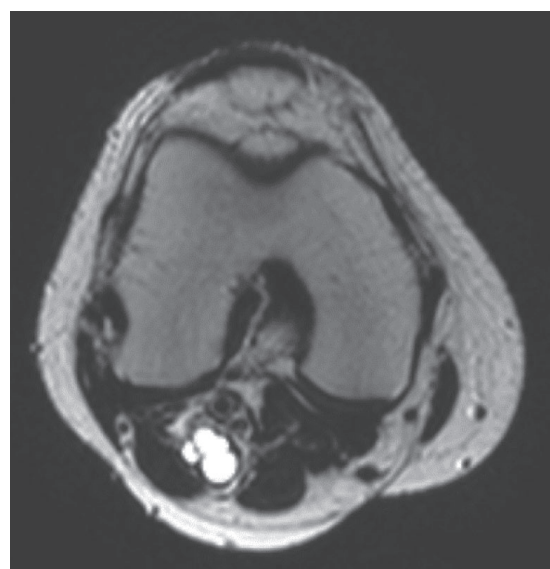


Fig. 3. Magnetic resonance imaging of the lower extremity at the level of the knee joint, axial images in T2 mode. Cyst-like changes in the area of the vascular-nerve bundle of the popliteal region

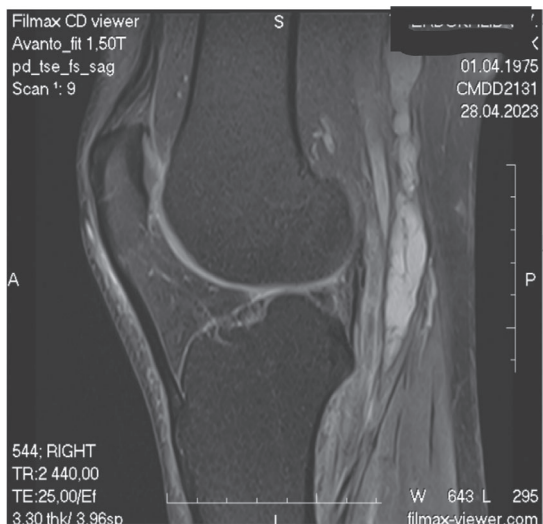


Fig. 4. Magnetic resonance imaging of the right knee joint, sagittal images in the PD-fsat mode. Intra-neural ganglion

and tibial nerves is registered (the strength of the flexor muscles of the right foot is preserved to 26%, the extensor muscles of the left foot to 69% of normal). The conduction speed of the nerve impulse by motor and sensory fibers of the right tibial nerve is reduced. Reflex excitability of the spinal motoneurons of the lumbar thickening on the right is 2.7%, on the left is 43.2% (normal 17–27%), ENMG signs of the pronounced axonal demyelizing motor-sensory lesion of the tibial portion of the right sciatic nerve. Decreased function of the L4-L5 roots on the left.

28.04.2023 the patient was consulted by a traumatologist who, taking into account the etiopathogenesis of the disease, recommended an MRI of the right knee joint.

On the same day, April 28, 2023, an MRI of the right knee joint was performed.

As we can see on Fig. 4, at the MRI of the knee, presence of the intra-neural ganglion cyst of the peroneal nerve was diagnosed and confirmed. MRI conclusion: MR signs of peripheral subcapsular damage of the posterior horn of the medial meniscus, degenerative changes in the lateral meniscus, anterior horn and body of the medial meniscus (grade 2 by Stoller), third-degree chondromalacia of the medial facet of the kneecap, ligamentopathy of the anterior cruciate ligament, osteoarthritis of the I-II stage, quadriceps tendinopathy, swelling of prepatellar soft tissues.

The detected multicystic fluid collector along the course of the vascular-nerve bundle, according to MR characteristics, corresponds to peroneal intra-neural ganglion cysts. Detected changes in the MR signal from the belly of the popliteal muscle require differential diagnosis between neurotrophic and edematous changes.

Soon 8.06.2023, after pre-operative examinations, surgical removal of the cyst with excision of its walls and preserving the integrity of the sciatic and fibular nerves was performed (Fig. 5).

During the surgery, neurolysis of the fibular nerve was performed at the level of the fibula shin (Fig. 5). Also denervation of the branch of the peroneal nerve to the capsule of the medial compartment of the knee was performed. Neurolysis of the sciatic nerve was performed, the epineurium was dissected and the intra-neural ganglion was resected.

The medial compartment of the knee was mobilized, resection of the articular surfaces was performed, and the connection of the joint with the INCG was disconnected. The early postoperative period was uneventful, the postoperative wound healed with primary intention.

Monitoring of the physical condition of the right lower limb in dynamics was recommended.

On 20.07.2023, the patient came for ENMG monitoring of the right lower limb.

The conclusion of the control ENMG: compared to 21.04.2023, a negative dynamic is observed: the muscle response to stimulation of the right fibular and tibial nerves

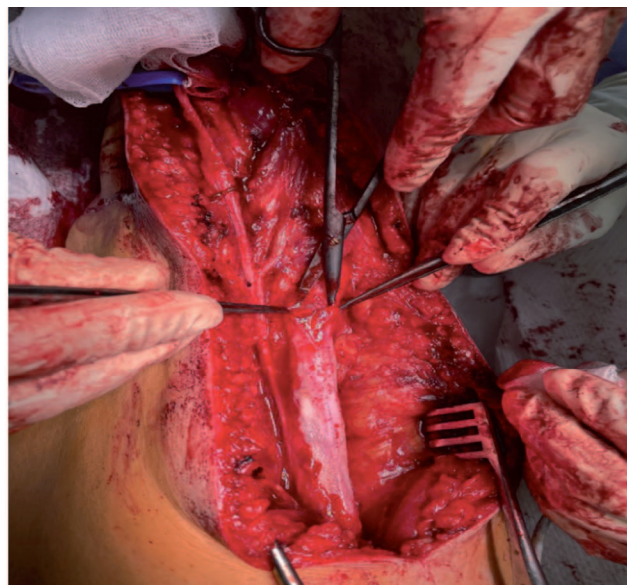
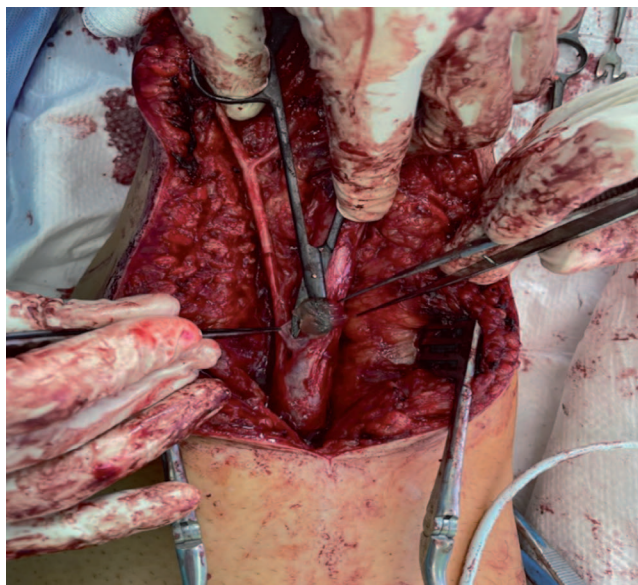


Fig. 5. Neurolysis of the peroneal nerve during surgery

decreased (the strength of the flexor muscles of the right foot remained up to 22%, the extensor muscles of the right foot – up to 60%, the left – up to 68% of the normal). The conduction speed by motor and sensory fibers of nerves on the right is reduced. Reflex excitability of spinal motoneurons of the lumbar thickening on the right – 4%, on the left – 44.8% (normal 17–27%). Conclusion: ENMG signs of the pronounced axonal-demyelinating motor-sensory lesion of the tibia and fibula nerves (at the level of the knee joint).

During the examination 1.5 months after the operation, the patient noted a slight recovery of sensitivity in the area of the lower leg and foot, the burning pain no longer bothered him. The feeling of numbness still remained, but it no longer prevented him from physical activities and work.

The concept and pathogenesis of intraneural ganglia has been the subject of research, debate, and controversy for 200 years [4, 5]. Intraneural ganglion cyst of the sciatic and peroneal nerve is a rare pathology in the adult population, mostly occurring in young men with an average age of 34 years. The articular (synovial) theory of pathogenesis describes a common origin of intraneural cysts, even if they arise in unusual locations [6]. In this clinical case, the connection of the intraneural ganglion with the proximal intertibial joint was found and resected intraoperatively.

The «gold standard» of INCG diagnostics is MRI. Magnetic resonance imaging provides a better assessment of the regional anatomic relationships, including the connection to the joint through the pedicle and the extra- or intraneural location of the cyst [7–9]. Ultrasound is another method for detection of the soft tissue masses and can be useful in unclear cases, but this method has certain limitations, such as difficulty in differentiating between benign and malignant tumors and detecting of the cyst-to-joint connections [10–13].

The treatment strategy is complete surgical removal and excision of the intraneural cyst. Targeted and precise dissection with the help of a surgery microscope often allows complete removal of the cyst without damaging the

nerve bundles, thus creating conditions for good functional recovery. Literature data indicate recovery of limb function within 45 days to 1 year after surgical removal of the cyst [14–17]. But another article reported that despite surgical removal, sometimes neurological symptoms (foot drop) persist without recurrence of the cyst [18, 19].

The degree of recovery depends mostly, unfortunately, not on the skill of the surgeon, but on the early diagnosis of the cyst. According to the literature data, late diagnosis or late referral to the hospital is considered to be 7 and more months after the onset of nerve palsy [20–25]. In this clinical case, the delay in surgical treatment arose as a result of erroneous conclusions regarding the ultrasound picture of the pathological condition at the beginning of the disease. The combination of thorough knowledge of anatomy and ultrasound semiotics, the clinical experience of the operator with the capabilities of modern equipment is decisive in the verification of pathological changes and selection of the optimal treatment tactics.

CONCLUSIONS

An intraneural ganglion cyst of the sciatic and peroneal nerves is a rare cause of peripheral neuropathy, which is completely curable with timely surgical intervention, but requires the awareness of doctors of various specialties regarding this pathology to avoid errors in differential diagnosis and treatment approaches. Knowledge of the articular theory of the pathogenesis of INCG can improve the results of surgical treatment to avoid recurrence. Early diagnosis and surgical treatment play a crucial role in the full recovery of motor and sensory functions.

Conflict of interest. The authors declare no conflict of interest.

Contributions of the authors. All authors made substantial contributions to the design, execution, and analysis of the study. All authors checked and confirmed the accuracy of the manuscript before submission.

Information about author

Khimion Liudmyla B. – MD, PhD, DSc, Professor, Head of the Department of Internal Diseases, Family Medicine, Hematology and Transfusiology, Shupyk National Healthcare University of Ukraine, Kyiv. *E-mail: ludmilahimion@hotmail.com*
ORCID: 0000-0001-7699-8725

Tymoshchuk Lilia S. – MD, PhD, Assistant of Professor, Department of Internal Diseases, Family Medicine, Hematology and Transfusiology, Shupyk National Healthcare University of Ukraine, Kyiv
ORCID: 0000-0003-2412-6866

Kicha Nataliia V. – MD, PhD, Associate Professor, Department of Internal Diseases, Family Medicine, Hematology and Transfusiology, Shupyk National Healthcare University of Ukraine, Kyiv. *E-mail: kicha0514@gmail.com*
ORCID: 0000-0002-2394-9564

Sytiuk Tetiana O. – MD, PhD, Associate Professor, Department of Internal Diseases, Family Medicine, Hematology and Transfusiology, Shupyk National Healthcare University of Ukraine, Kyiv. *E-mail: sytuktanya@ukr.net*
ORCID: 0000-0003-3828-3600

Danyliuk Svitlana V. – MD, PhD, Associate Professor, Department of Internal Diseases, Family Medicine, Hematology and Transfusiology, Shupyk National Healthcare University of Ukraine, Kyiv. *E-mail: svdan62@gmail.com*
ORCID: 0000-0001-7753-9088

Povetkina Tetiana M. – MD, PhD, Associate Professor, Department of Internal Diseases, Family Medicine, Hematology and Transfusiology, Shupyk National Healthcare University of Ukraine, Kyiv
ORCID: 0000-0002-9442-2188

Chernyak Olga S. – MD, Head of Ultrasound Diagnostic Department, Municipal Non-Commercial Enterprise of Kyiv regional council «Kyiv Regional Clinical Hospital», Kyiv. *E-mail: chemiak.os@gmail.com*

Urupa Irina P. – MD, Ultrasound Diagnostic Physician, Municipal Non-Commercial Enterprise of Kyiv regional council «Kyiv Regional Clinical Hospital», Kyiv. *E-mail: urandom1998@gmail.com*

Dzyhar Oleksandr V. – MD, Radiologist, SI «The Institute of Traumatology and Orthopedics» by NAMS of Ukraine, Kyiv. *E-mail: megapevt@gmail.com*

Відомості про авторів

Хіміон Людмила Вікторівна – д-р мед. наук, проф., завідувач, кафедра терапії, сімейної медицини, гематології і трансфузіології, Національний університет охорони здоров'я України імені П. Л. Шупика, м. Київ. *E-mail: ludmilahimion@hotmail.com*

ORCID: 0000-0001-7699-8725

Тимошук Лілія Сергіївна – канд. мед. наук, асистент, кафедра терапії, сімейної медицини, гематології і трансфузіології, Національний університет охорони здоров'я України імені П. Л. Шупика, м. Київ. *E-mail: liliyatimoshuk@gmail.com*

ORCID: 0000-0003-2412-6866

Кіча Наталія Василівна – канд. мед. наук, доцент, кафедра терапії, сімейної медицини, гематології і трансфузіології, Національний університет охорони здоров'я України імені П. Л. Шупика, м. Київ. *E-mail: kicha0514@gmail.com*

ORCID: 0000-0002-2394-9564

Ситюк Тетяна Олександрівна – канд. мед. наук, доцент, кафедра терапії, сімейної медицини, гематології і трансфузіології, Національний університет охорони здоров'я України імені П. Л. Шупика, м. Київ. *E-mail: syuktanya@ukr.net*

ORCID: 0000-0003-3828-3600

Данилюк Світлана Володимирівна – канд. мед. наук, доцент, кафедра терапії, сімейної медицини, гематології і трансфузіології, Національний університет охорони здоров'я України імені П. Л. Шупика, м. Київ. *E-mail: svdan62@gmail.com*

ORCID: 0000-0001-7753-9088

Поветкіна Тетяна Миколаївна – канд. мед. наук, доцент, кафедра терапії, сімейної медицини, гематології і трансфузіології, Національний університет охорони здоров'я України імені П. Л. Шупика, м. Київ

ORCID: 0000-0002-9442-2188

Черняк Ольга Сергіївна – завідувачка, відділення ультразвукової діагностики, КНП КОР «Київська обласна клінічна лікарня», м. Київ. *E-mail: cherniak.os@gmail.com*

Урупа Ірина Петрівна – лікар відділення ультразвукової діагностики, КНП КОР «Київська обласна клінічна лікарня», м. Київ. *E-mail: urandom1998@gmail.com*

Дзигар Олександр Васильович – рентгенолог, ДУ «Інститут травматології та ортопедії НАМН України», м. Київ. *E-mail: megapevt@gmail.com*

REFERENCES

- Spinner RJ, Harish S, Amrami KK. An historical perspective on ulnar intraneural ganglion cysts and their joint origins. *Hand (N Y)*. 2014;9(3):395-8. doi: 10.1007/s11552-014-9608-z.
- Lisovski V, Minders M. Intraneural ganglion cyst: a case report and a review of the literature. *Acta Med Lit.* 2019;26(2):147-51. doi: 10.6001/actamedica.v26i2.4036.
- Byung-Chul S, Jun-Gyu C, Hak-Cheol K. Ulnar neuropathy due to intraneural ganglion cyst of the ulnar nerve at the elbow. *Indian J Neurosurg*. 2018;7(7):260-4.
- Spinner RJ, Scheithauer BW, Amrami KK. The unifying articular (synovial) origin of intraneural ganglia: evolution-revelation-revolution. *Neurosurgery*. 2009;65(4):115-24. doi: 10.1227/01.NEU.0000346259.84604.D4.
- Spinner RJ, Vincent JF, Wolanskyj AP, Scheithauer BW. Intraneural ganglion cyst: a 200-year-old mystery solved. *Clin Anat*. 2008;21(7):611-8. doi: 10.1002/ca.20709.
- Lovaglio AC, Mansilla B, Cejas C, Spinner RJ, Socolovsky M. Femoral intraneural ganglion cyst: the first confirmed case report. *Br J Neurosurg*. 2023;37(5):1251-3. doi: 10.1080/02688697.2020.1842853.
- Lenartowicz KA, Wolf AS, Desy NM, Strakowski JA, Amrami KK, Spinner RJ. Preoperative Imaging of Intraneural Ganglion Cysts: A Critical Systematic Analysis of the World Literature. *World Neurosurg*. 2022;166:968-79. doi: 10.1016/j.wneu.2022.08.005.
- Huntington LS, Talia A, Devitt BM, Batta L. Management and outcomes of proximal tibiofibular joint ganglion cysts: A systematic review. *Knee*. 2022;37:60-70. doi: 10.1016/j.knee.2022.05.009.
- Lenartowicz KA, Murthy NK, Desy NM, De La Pena NM, Wolf AS, Wilson TJ, et al. Does complete regression of intraneural ganglion cysts occur without surgery? *Acta Neurochir (Wien)*. 2022;164(10):2689-98. doi: 10.1007/s00701-022-05311-w.
- Aymen F, Jacem S, Youssef O, Issam A, Abderrazek A. Peroneal nerve palsy caused by a synovial cyst of the proximal tibiofibular joint: a report of two cases and review of the literature. *Pan Afr Med J*. 2019;34:115. doi: 10.11604/pamj.2019.34.115.18339.
- Khan G, Kazmi Z, Khan B, Khan N, Datta S. Ganglion cyst at the proximal tibiofibular joint - A rare cause of compression neuropathy of the peroneal nerve. *Radiol Case Rep*. 2021;17(1):99-102. doi: 10.1016/j.radcr.2021.10.004.
- Thalla N, White WD, Mansfield JT, Souza JM, Miller ME. Spontaneous Proximal Tibiofibular Joint Ganglion Cyst as a Rare Cause of Acute Foot Drop: A Case Report. *J Musculoskelet Disord Treat*. 2021;7:095. doi: 10.23937/2572-3243.1510095.
- Smith BW, Jack MM, Powell GM, Frick MA, Amrami KK, Spinner RJ. High-resolution MRI of a peroneal intraneural ganglion cyst arising from the knee joint: illustrative case. *J Neurosurg Case Lessons*. 2021;1(21):CASE21130. doi: 10.3171/CASE21130.
- Wilson TJ, Stone JJ, Howe BM, Rock MG, Spinner RJ. Joint Outcomes Following Surgery for Superior Tibiofibular Joint-Associated Peroneal Intraneural Ganglion Cysts. *Neurosurgery*. 2020;86(3):383-90. doi: 10.1093/neuros/nyz205.
- Marathe A, Song B, Sulapas I, Jayaram P. Doppler Ultrasound Utility in Intraneural Ganglion Cyst Diagnosis. *Am J Phys Med Rehabil*. 2022;101(5):e80. doi: 10.1097/PHM.0000000000001967.
- Norbury JW, Guo Y, Boyer PJ, Zeri RS. The Power of Doppler in the Popliteal Fossa: Sonographic Diagnosis of a Fibular Nerve Neurofibroma in a Patient With Posterior Knee Swelling. *Am J Phys Med Rehabil*. 2018;97(10):e100-e101. doi: 10.1097/PHM.0000000000000928.
- Pemmari A, Mäkelä K, Niemi J, Kiekara T, Himanen SL. Large Intraneural Ganglion Cyst in the Peroneal Nerve. *Case Rep Neurol*. 2022;14(1):44-50. doi: 10.1159/000522061.
- Wilson TJ, Mauermann ML, Rock MG, Spinner RJ. Outcomes following surgery for peroneal intraneural ganglion cysts. *Muscle Nerve*. 2018;57(6):989-93. doi: 10.1002/mus.26062.
- Della Vecchia G, Baldi A, Passavanti MB, Lucariello A, De Luca A, De Blasis P. Acute Foot Drop Caused by Intraneural Ganglion Cyst of the Peroneal Nerve: Literature Review and Case Report. *J Pers Med*. 2023;13(7):1137. doi: 10.3390/jpm13071137.
- Yunga TJ, Maddy K, Errante EL, Costello MC, Steinlauf S, Burks SS. Recurrent Peroneal Intraneural Ganglion Cyst: Management and Review of the Literature. *Cureus*. 2023;15(5):e38449. doi: 10.7759/cureus.38449.
- Panwar J, Mathew A, Thomas BP. Cystic lesions of peripheral nerves: Are we missing the diagnosis of the intraneural ganglion cyst? *World J Radiol*. 2017;9(5):230-44. doi: 10.4329/wjr.v9.i5.230.
- Bucher F, Maerz V, Obed D, Vogt PM, Weyand B. Intraneural Ganglion of the Peroneal Nerve-A Rare Cause of Pediatric Peroneal Nerve Palsy: A Case Report. *European J Pediatr Surg Rep*. 2022;10(1):33-6. doi: 10.1055/s-0042-1742608.
- Sim J, Kwak H, Lee S, Min K. Peroneal neuropathy caused by an extraneural ganglion cyst in the supracondylar area of the femur: A case report. *Medicine (Baltimore)*. 2020;99(37):e22123. doi: 10.1097/MD.0000000000002123.
- Wilson TJ, Stone JJ, Howe BM, Rock MG, Spinner RJ. Joint Outcomes Following Surgery for Superior Tibiofibular Joint-Associated Peroneal Intraneural Ganglion Cysts. *Neurosurgery*. 2020;86(3):383-90. doi: 10.1093/neuros/nyz205.
- Lee JG, Peo H, Cho JH, Kim DH. Intraneural ganglion cyst of the lumbosacral plexus mimicking L5 radiculopathy: A case report. *World J Clin Cases*. 2021;9(17):4433-40. doi: 10.12998/wjcc.v9.i17.4433.

Стаття надійшла до редакції 30.10.2023. – Дата першого рішення 07.11.2023. – Стаття подана до друку 12.12.2023